第 48 卷第 7 期
2021 年 7 月

湖南大学学报（自然科学版）
Journal of Hunan University（Natural Sciences）

Vol. 48. No. 7.
July 2021

Open Access Article

THE RESULTS OF THE USE OF LOW-INTENSITY PHOTODYNAMIC LASER THERAPY IN PATIENTS WITH DYSTROPHIC DISEASES OF THE VULVA

Delya Fozilovna Porsokhonova
Doctor of Medical Science, Senior Researcher, Head of Research Group of Experimental Scientific Laboratory (ESL), Study of STIs and Reproductive Disorders, Republican Specialized Scientific and Practical Medical Center of Dermatovenerology and Cosmetology, Ministry of Health of the Republic of Uzbekistan, Tashkent, Uzbekistan
e-mail: delya.porsokhonova@mail.ru

Sevara Nodirbekovna Rakhmatullaeva
Junior Researcher of the Applied Project PZ-20170927338, Republican Specialized Scientific and Practical Medical Center of Dermatovenerology and Cosmetology Ministry of Health of the Republic of Uzbekistan, Tashkent, Uzbekistan
e-mail: sevararakhmatullaeva.sr@gmail.com

Marianna Leontevna Rosstalnaya
Junior Researcher of the Applied Project PZ-20170927338, Republican Specialized Scientific and Practical Medical Center of Dermatovenerology and Cosmetology Ministry of Health of the Republic of Uzbekistan, Tashkent, Uzbekistan

Bobir Shavkatovich Fattakhov
PhD, Republican Specialized Scientific and Practical Medical Center of Dermatovenerology and Cosmetology, Ministry of Health of the Republic of Uzbekistan, Tashkent, Uzbekistan

Jahongir Raxmatovich Turdiev
Republican Specialized Scientific and Practical Medical Center of Dermatovenerology and Cosmetology Ministry of Health of the Republic of Uzbekistan, Tashkent, Uzbekistan

Abstract

According to the current classification, among the pretumor diseases of the vulva, united by the single term “Dystrophic diseases of the vulva” (DDV), there are sclerotic lichen (the clinical historical term “kraurosis of vulva”), squamous hyperplasia of the vulva (a similar treatment is “leukoplakia”) and other dermatoses. The aim of our study was to evaluate the results of complex therapy for patients with DDV using a low-intensity photodynamic laser.

We examined 78 patients with dystrophic diseases of the vulva, among which there were simple lichen vulva (limited neurodermatitis), scleroatrophic lichen of vulva (SAL), leukoplakia. The diagnosis was histologically confirmed.

Received: April 12, 2021 / Revised: May 11, 2021 / Accepted: June 13, 2021 / Published: July 23, 2021
About the authors: Delya Fozilovna Porsokhonova, delya.porsokhonova@mail.ru
Corresponding author- Delya Fozilovna Porsokhonova, delya.porsokhonova@mail.ru

Late treatment and low adherence to examination and treatment by women with DDD may contribute to the development of dystrophic and dysplastic processes in the vulva and lower third of the vagina.
Keywords: dermatology, skin disease, gynecology, cosmetology, vulva

抽象的

根据目前的分类，在外阴癌前疾病中，由单一术语“外阴营养不良性疾病”（DDV）联合起来，有硬化性苔藓（临床历史术语“外阴黑斑病”）、鳞状细胞增生症。 外阴（类似的治疗方法是“白斑病”）和其他皮肤病。 我们研究的目的是评估使用低强度光动力激光对 DDV 患者进行复杂治疗的结果。

我们检查了 78 名患有营养不良性外阴疾病的患者，其中有单纯性外阴苔藓（局限性神经性皮炎）、外阴硬化性苔藓（SAL）、白斑。 诊断得到组织学证实。

DDD 妇女的晚期治疗和对检查和治疗的依从性低可能导致外阴和阴道下三分之一的营养不良和发育不良过程的发展。

关键词：皮肤科，皮肤病，妇科，美容，外阴

Introduction

According to the current classification, among the pretumor diseases of the vulva, united by the single term “Dystrophic diseases of the vulva” (DDV), there are sclerotic lichen (the clinical historical term “kraurosis of vulva”), squamous hyperplasia of the vulva (a similar treatment is “leukoplakia”) and other dermatoses [1, 2, 3]. According to World statistics, DDVs occupy 0.06% of the total number of dermatological, oncological, gynecological diseases [4, 5, 6, 7]. Clinically, these processes have similar manifestations. Kraurosis and leukoplakia are not referred to precancerous diseases of the vulva by chance; against their background, malignant processes can occur in 4–49% of cases [8, 9]. The problem of early treatment of this group diseases is especially important in connection with the frequent transformation of the latter into intraepithelial dysplasia of the vulva and vagina (Vulvar intraepithelial neoplasia (VIN)), as well as into cancer, especially in patients of postmenopausal age [10, 11]. The selection of treatment methods, of course, is associated with the search for the causes of the disease. Difficulties often arise due to the absence of obvious factors leading to dystrophy and dysplasia. It is still unclear whether these processes are sequential stages or arise autonomously. Research in this direction has been carried out for many decades; however, a clear answer to this question has not been received. To date, the theory of hormonal imbalance, neurogenic, viral-infectious, autoimmune, and genetic theories remain relevant [12, 13, 14, 15].

The **aim** of our study was to evaluate the results of complex therapy for patients with DDV using a low-intensity photodynamic laser.

Material And Methods

We examined 78 patients with dystrophic diseases of the vulva, among which there were simple lichen vulva (limited neurodermatitis), scleroatrophic lichen of vulva (SAL), leukoplakia. The diagnosis was histologically confirmed.

The age of the patients ranged from 6 to 68 years, but the age group from 45 to 68 years prevailed. The duration of the disease ranged from several

months to 10 years. Basically, patients complained of itching, burning, discomfort, impaired urination, discoloration of the skin and mucous membrane, tissue structure in the vulva with varying degrees of severity. Patient selection criteria were chronic, long-term, recurrent, non-conservative changes in the vulva. Previously, all patients underwent clinical and anamnestic testing in order to identify the cause of the disease, screening for infections of the urogenital tract, including sexually transmitted infections (STI). Screening for infections of the urogenital tract was performed by taking a scraping from the urethral and cervical canals and subsequent microscopic, bacteriological and PCR (polymerase chain reaction) studies.

Protocol of laser therapy: Clinical studies were conducted by us at various clinical bases of the Republican Specialized Scientific and Practical Medical Centre of Dermatology and Venereology of the Ministry of Healthcare of Uzbekistan (Tashkent) and regional dermatovenerological dispensaries of the Republic of Uzbekistan. All studies are open, prospective, placebo-controlled. Each patient received written consent to participate in the study. When selecting the contingent of patients, the duration of the disease, the presence of concomitant diseases, gender, age, and the results of previous treatment were taken into account. For the diagnosis and monitoring of the dynamics of the disease, currently accepted clinical, functional, serological, morphological, laboratory research methods. Patient groups were formed in accordance with the principles of randomization and stratification.

Diagnosis and examination of patients with DDV included visual examination, vulvoscopy with Schiller's test, and cytological examination. To exclude vulvar cancer, a biopsy is required, followed by histological examination. Our method of treatment, unlike traditional ones (using estrogens, progesterone, androgens, glucocorticoids), does not prescribe hormone therapy, since hormone therapy has a temporary effect and inevitably leads to tissue atrophy, which in this disease can only aggravate the condition of patients. We also refused to use drugs that affect the nervous system (sedatives, antidepressants et c.t.) and antihistamines, since they all give a temporary effect.

The main objective of the treatment, we see the elimination of infectious agents taking into account their sensitivity to antibiotics and rehabilitation through exposure to low-intensity laser therapy with a photodynamic effect. Our proposed method involves the combined use of anti-inflammatory therapy taking into account the identified pathogens in combination with laser therapy with the apparatus of laser therapy (ALT) “Vostok Delta 03” (developed by Prof. Mavlyankhodzhaev R.Sh. et al.) domestic portable laser device with a photodynamic range of 630 μm, in a non-contact manner with the terminal installed 1 cm from the affected surface by scanning with a healthy 1-2 cm skin, power up to 1 W, pulse frequency 24 Hz, modulation frequency 1.2 Hz, exposure time 10-20 minutes, depending on the depth and area of the lesion. Laser therapy course 10 daily sessions. Number of courses 1-2. Our method is aimed at eliminating infection as a possible cause of kraurosis, preventing candidiasis complications, immunotherapy, as an opportunity to eliminate chronic inflammation and relapse of infection. Photodynamic laser therapy is designed not only to supplement the antibacterial effect that was proved in previous studies, but also to achieve apoptosis of cells infected with the virus (Herpes simplex virus (HSV), Human papillomavirus (HPV), Cytomegalovirus (CMV)), improve microcirculation, and start reparative processes.

The method allows to avoid surgical and surgical laser exposure in some cases, reduces the number of courses of therapy to 1-2 (traditionally: 5-12), is non-invasive, affordable, devoid of side effects.

A controlled study of the clinical manifestations of the disease, accounting for subjective and objective indicators of the examination of internal organs and systems was carried out for all patients on the first day of admission to inpatient treatment, on the 8th and 10th days of treatment.

Based on a large number of randomized controlled clinical trials and their subsequent analysis, we were able to show the effectiveness of complex therapy using PDT in patients with DDV, which corresponds to the level of evidence B - relative evidence: there is enough evidence to recommend this proposal.

Results

Analysis of anamnestic data showed that patients with DDV had a low adherence to treatment. The causes of late treatment were most often constraint, a feeling of awkwardness associated with the intimate nature of the problem, long-term attempts at self-treatment with corticosteroid and estrogen-containing creams. It should be noted that in many patients the phenomenon of genital skin atrophy began, associated with prolonged uncontrolled use of corticosteroid-containing ointments and creams. Before contacting us, the patients mainly passed an analysis of the secreted urogenital tract, which included only smear microscopy, or inoculation on the accompanying microbial flora. Most patients excluded the likelihood of infection and inflammation influencing the development of DDV due to scanty discharge from the genital tract. On average, from the beginning of anxiety to going to the doctor, it took from 6 months to 6 years.

One or another pathogen from the STI group or from the composition of the concomitant microflora in the form of mono-infection or in the mixed variant was detected in 65 (83.3%) patients. The results of a study of the microflora of the urogenital tract of women with DDD are as follows: Ureaplasma urealyticum was found in 26 (33.3%) cases, Chlamydia trachomatis - 3 (3.8%), HPV 16/18 - 18 (23.1%), HSV -1type -5 (6.4%), HSV-2 type - 7 (9.0%) Gardnerella vaginalis-13 (16.7%), fungi of the genus Candida - 39 (50.0%), St. Epidermidis- 3 (3.8%), St.haemolyticus-5 (6.4%), Enterobacter-15 (19.2%), Escherichia coli-2 (2.6%), Enterococci-10 (12.8%). Thus, Ureaplasma urealyticum (33.3%), HPV type 16/18 (23.1%) and Candida albicans (50.0%) were the most common pathogens for dysplastic and dystrophic genital diseases, which may indicate their starting, and on the aggravating role in the origin of dystrophy and dysplasia.

The identification of these pathogens served as the basis for the inclusion of antibacterial, antiviral, and anti-candidiasis drugs in the complex therapy. As a result of the therapy, on the 3-4th day from the start of treatment, itching and inflammation stopped in 11 patients. And by the 9-10th day of treatment, there was a significant softening of the skin of the vulva and perianal region, partial resorption of the infiltration zone, and restoration of the skin pattern. As a result of using this method, 83.3% efficiency was obtained after the first course of therapy. Relapse of pruritus was noted in 5 patients 1 month after the end of treatment; they underwent a second course of laser therapy. The introduction of the proposed method into clinical practice not only reduced the length of hospital stay, but also in many cases allows refusing

hospitalization of patients, increasing the effectiveness of outpatient treatment. Reducing the length of hospital stay and temporary incapacity for work, increasing the effectiveness of outpatient treatment, limiting the number of patients requiring hospitalization, and most importantly reducing the cost of drugs and rehabilitation of disabled people, determined the economic effect of the studies.

Discussion

Our results of examination and treatment indicate the important role of low adherence to treatment of patients with DDD, among other reasons. The interdisciplinary nature of the disease, due to the intimate nature of the problem, leads patients primarily to gynecologists, who are often limited to prescribing only external therapy without special examination methods, such as histological analysis, PCR, complex bacteriological examination for infections, hormonal testing, etc. Frequent detection of pathogens such as Ureaplasma Urealyticum, Candida, HPV type 16/18, Enterobacter may indicate a direct or indirect role of these pathogens in the origin of DDV. The effective use of complex low-intensive photodynamic laser therapy and anti-inflammatory treatment, taking into account the identified pathogens in the treatment of DDD, is most likely associated with the activation and restoration of microcirculation and regeneration processes in the vulva, normal microflora of the urogenital tract and the elimination of the prurigenic effect of some products of chronic inflammation and infection (toxins, kinins and c.t.).

Conclusion

Late treatment and low adherence to examination and treatment by women with DDD may contribute to the development of dystrophic and dysplastic processes in the vulva and lower third of the vagina.

Pathogens such as Ureaplasma Urealyticum, Candida, HPV type 16/18, Enterobacter are detected in patients with DDV with an increased frequency, which may indicate a direct or indirect role of these pathogens in the origin of DDV.

The use of anti-inflammatory therapy, taking into account the identified pathogens in combination with low-intensity laser therapy with a photodynamic range, makes it possible to stop itching and chronic inflammation in the first stage and restore microcirculation and tissue regeneration in the subsequent stages of treatment.

Patient M. D., 7 years old. D-s: scleroatrophic lichen vulva, before and after treatment

Patient N. R.61years old. D-s: scleroatrophic lichen of vulva, before and after treatment

Patient G. Sh. 44 years old. D-s: Limited vulvar neurodermatitis, before and after treatment

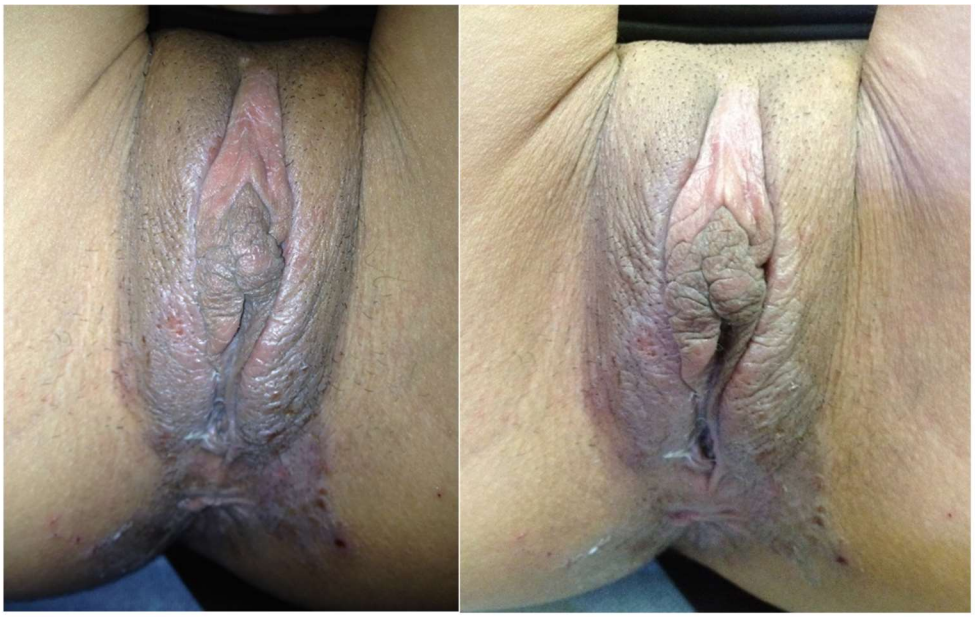

Patient S. Yu. 34 years old. D-s: Scleroatrophic lichen, before and after treatment

References

1. Ashrafyan L. A., Kharchenko N. V., Kiselev V. I. et al. Cancer of the vulva: epiopathogenetic concept. M., 2006, p. 192.

2. Kuznetsov V.V., Korzhevskaya E.V. Squamous cell carcinoma of the vulva. / Rational Pharmacotherapy in Oncology: A Guide for Practitioners under the General Ed. Academician of RAS M.I. Davydov, Professor V.A. Gorbunova - M .: Publishing house "Literra", 2015. - P. 441-444

3. Makarov O.V., Khashukoeva A.Z., Kupeeva E.S. Photodynamic therapy as a promising method for the treatment of dystrophic diseases of the vulva // Lech. doctor. 2011. No. 11. P. 28.

4. Sadykov R.A., Kasymov K.R., Sadykov R.R. Technical and scientific aspects of photodynamic therapy. - Tashkent. 2012.-167p.

5. Tsyb A.F. Clinical aspects of photodynamic therapy / A.F. Tsyb, M.A. Kaplan, Yu.S. Romanko, V.V. Popuchiev // Kaluga: Publishing house of scientific literature N.F. Bochkareva, 2009 - 203 p.
6. Sharapova L.E. On the etiology and pathogenesis of chronic dystrophic diseases of the vulva // Russian Bulletin of Obstetrics and Gynecology. - 2010. - No. 1.- S. 29-34.
7. Greer BE, Koh WJ. New NCCN Guidelines for Vulvar Cancer. J Natl Compr Canc Netw 2016; 14: 656–658.Greer BE, Koh WJ. New NCCN Guidelines for Vulvar Cancer. J Natl Compr Canc Netw 2016; 14: 656–658.
8. Micheletti L, Preti M, Radici G, Boveri S, Di Pumpo O, Privitera SS, Ghiringhello B, Benedetto C. Vulvar lichen sclerosus and neoplastic transformation: a retrospective study of 976 cases. Journal of lower genital tract disease. 2016 Apr 1;20(2):180-3.
9. Dunaevskaya V, Tzerkovsky DA. Photodynamic Therapy in Vulvar Dystrophy Treatment. Archives of Clinical and Biomedical Research. 2018;2(2):42-51.
10. Singh N, Ghatage P. Etiology, clinical features, and diagnosis of vulvar lichen sclerosus: a scoping review. Obstetrics and gynecology international. 2020 Apr 21;2020.
11. Levine EM. Lower Genital Tract Disease. InAmbulatory Gynecology 2018 (pp. 163-174). Springer, New York, NY.
12. Goodman A. Delay in diagnosis and increasing incidence of vulvar cancer: a root cause analysis. Menopause. 2021 Feb 1;28(2):111-2.
13. Schwartz M, Blank SV. Vulvar Cancer. Obstetrics and Gynecology. 2020 Aug 12:351-8.
14. Bratila E, Cirstoiu M, Mehedintu C, Berceanu C, Bohiltea R, Toader O, Comandasu DE. The effect of chronic vulvar dystrophy on urinary continence in patients at climacterium. Maturitas. 2017 Jun 1;100:169.
15. Singh N, Mishra N, Ghatage P. Treatment Options in Vulvar Lichen Sclerosus: A Scoping Review. Cureus. 2021 Feb;13(2).